

Mini-Reviews

Breast Disorders in Children and Adolescents

Mary E. Fallat, MD and Romeo C. Ignacio, Jr, MD

Department of Surgery, University of Louisville, Louisville, Kentucky, USA

Key Words. Breast—Fibroadenoma—Breast cancer—Breast neoplasms—Nipple discharge—Duct hyperplasia

Objectives

1. To understand the embryology and associated disorders of breast development
2. To understand an approach to recognition and diagnosis of breast disease in female children and adolescents
3. To understand the fundamentals of treatment of pediatric and adolescent breast disorders

Introduction

Although the vast majority of breast disorders in pediatric patients are benign, the presence of any breast complaint frequently raises parental concerns of a potential cancer.^{1,2} A thorough knowledge of the various breast pathologies, a complete physical examination, and diagnostic evaluation as indicated are needed to reassure the patient and the parents and to avoid missing any rare malignant lesion.^{3,4}

Pediatric breast disorders can occur at any age. The chief complaints can include abnormal enlargement, asymmetric growth, nipple discharge, breast pain, skin changes, or a palpable mass. The clinical presentation and age of the patient will determine if radiographic studies are warranted. Many breast lesions require only clinical examination and reassurance, and possibly observation. However, persistent breast complaints or worsening symptoms may require biopsy or excision. A prompt evaluation and diagnostic

plan are important in order to alleviate any emotional fears and to plan any necessary surgical therapy if warranted. This article reviews the various congenital, infectious, benign, and malignant disorders that can occur in female children and adolescent patients.

Embryology and Breast Development

- Beginning at 4 weeks of embryologic development, a pair of thickened longitudinal streaks of ectoderm are seen along the anterior abdominal wall from the axilla to the labia majora. Breast tissue can develop anywhere along these paired ectodermal ridges known as “milk lines,” “milk ridges,” or “Hughes lines.”⁵
- The proximal and distal ectodermal ridges atrophy by the tenth week of development except in the pectoral region. The remaining ectodermal tissue grows into the underlying mesenchyme and forms the primary mammary bud.
- Further growth and branching occurs from week 10–16 where lactiferous ducts are seen. These ducts continue to grow into the underlying mesenchyme and later develop into the fibrous and adipose tissue of the breast.
- The areola and nipple develop later in fetal development. A pigmented areola is seen at week 20–24. A true nipple is not present until later in the perinatal period, where it appears as an inverted structure.
- Estrogen influences the development of the breast buds during the last trimester until a true breast nodule forms. This breast nodule is palpable by 34 weeks of gestation.

Stages of Breast Development

- Various hormones strongly influence the development of breast tissue in the prepubertal and pubertal phases. Estrogen stimulates the growth of

Address correspondence to: Mary E. Fallat, MD, University of Louisville School of Medicine, Department of Surgery, Division of Pediatric Surgery, 315 E. Broadway Street, Suite 565, Louisville, KY 40202; E-mail: mefall01@louisville.edu

lactiferous ducts and fibroadipose tissue. Progesterone stimulates the development of lobular tissue and alveolar budding. Excessive prolactin can also stimulate newborn breast tissue to secrete milk.

- The breast tissue in the full-term newborn begins as a discrete, palpable nodule. The nodule may persist for the first 6–12 months and later involutes.
- Puberty is noticed by the development of a pubertal breast (thelarche) and the growth of pubic hair. The mean onset for breast development in the United States is 8.87 years in African-American girls and 9.96 years in white girls.⁶
- The Tanner stage describes the pubertal development of breasts into five stages⁷ (Table 1). Breast development normally is complete by 2–4 years after thelarche.
- Delayed breast growth is considered a lack of development by age 13.⁵ These patients require an extensive evaluation and referral to an endocrinologist for potential causes for delayed development such as eating disorders, Turner syndrome, chronic illnesses such as Crohn disease, or a sexual differentiation disorder.

Presentation

The majority of breast masses with the exception of infection are first noticed because of incidental palpation of a lump or thickening by either the parent or patient.² Infection may first be noticed as a firm area that is often sore to the touch, followed by localized erythema. Although many areas of concern in adolescents are noticed first by the patient, self-examination of the breast in adolescents is controversial, because the developing breasts are often asymmetric and palpably nodular due to the normal growth and development of breast tissue, and because of the extreme rarity of breast malignancies in girls under 18 years old. It is recognized that time might be better spent educating about the risks of drugs, alcohol, and smoking.

Table 1. Tanner Staging of Breast Development

Stage	Characteristics
1	Elevation of breast papilla only
2	Elevation of the breast bud and papillae as a small mound Enlargement of the areola diameter Areola becomes pinker
3	Further enlargement of the breast and areola with no separation of their contours. Montgomery's tubercles appear.
4	Further enlargement with projection of the areola and papilla to form a secondary mound above the level of the breast.
5	Projection of the papilla only, resulting from the recession of the areola to the general contour of the breast

Imaging

Ultrasound is the diagnostic test of choice to evaluate a palpable mass, but it is a poor screening examination.^{5,7} Fat is hypoechoic and glandular tissue is echogenic relative to hypoechoic fat. Ultrasound is ideal for differentiating solid from cystic masses. Mammography is relatively contraindicated in adolescent women and less helpful due to increased fibroglandular tissue in developing breasts leading to poor pathologic correlation.^{2,7} However, in cases of persistent nipple discharge without a palpable mass, oblique mammographic views done by an experienced breast radiographer may be helpful.

Disorders of Breast Development

Polythelia occurs in 2% of the population and can appear anywhere along the milk line. Polymastia or accessory breast tissue may accompany polythelia. Surgical intervention is considered for symptoms, which may include cyclical tenderness or irritation based on location of the tissue. Ectopic breast tissue can be seen in the axilla, presenting as a soft tissue mass that responds to cyclical hormone stimulation.⁴ Nipple inversion is a normal variant and often familial. It should be considered pathologic only if the condition was not initially present at birth but occurs subsequently, because new onset may represent infection or an occult tumor.

Neonatal hypertrophy can occur in either sex, results from maternal estrogen stimulation, and may be unilateral or bilateral. It may be associated with a clear or cloudy discharge (witch's milk), and may self-perpetuate with manipulation. Parents should be encouraged to avoid palpation of the breast area because the condition is self-limited.

Thelarche begins with the onset of puberty, is the first sign of puberty, and should occur by age 13.⁵ Breast asymmetry is common as the breasts are developing.^{2,7} The age of thelarche has been decreasing in the American population and also varies based on race. The mean onset for breast development in the United States is 8.87 years in African-American girls and 9.96 years in white girls.⁶ Premature thelarche is breast development before age 7 years in white girls and age 6 years in African-American girls. It often manifests as early as age 1–3 and may be unilateral or asymmetric. This early breast development may progress, remain stationary, or regress. It is usually benign and may be familial. Puberty occurs normally in these situations. A screening bone age may be done to determine the need for a more extensive workup for precocious puberty. Plasma estradiol may be elevated.

Amastia is a rare disorder and may be associated with other congenital anomalies of the chest wall such

as Poland's Syndrome. Small breasts with otherwise normal pubertal development are usually normal. If lack of breast development is associated with delayed puberty, a workup for ovarian failure is indicated. The causes of ovarian failure include sexual differentiation disorders such as gonadal dysgenesis, androgen insensitivity syndrome, or congenital adrenal hyperplasia; or other disorders including hypothyroidism or polycystic ovary syndrome.

Juvenile hypertrophy is a condition of pathologic overgrowth of the breasts. An end organ sensitivity to estrogens is one hypothesis.⁴ This condition may be familial. The usual onset is at menarche, it is usually symmetric, and each breast may weigh as much as 30–50 pounds. If asymmetric, there is a higher likelihood of a mass causing the condition, such as a giant fibroadenoma or lymphoma. Juvenile hypertrophy can lead to back and neck strain. Surgical intervention by reduction mammoplasty is often considered in the older teen or young adult once the breasts achieve maturity.

Tuberous breasts are breasts that have limited dimensions at the base with an overdeveloped nipple areolar complex. The condition may result from the use of exogenous steroids, and surgical options include mammoplasty, tissue expansion, or flap reconstruction.

Infections of the Breast and Nipple

Inflammatory disorders account for approximately 4% of all childhood breast conditions. Causes include local infection, epidermoid cysts, foreign bodies, trauma, nipple piercing, and folliculitis from shaving periareolar hair. Infection usually presents as localized tenderness and induration followed by appearance of erythema and then a fluctuant mass. Breast abscesses may occur at any age, including in infants. Initial management includes antimicrobial therapy. Aspiration or incision and drainage may be needed. Procedures in the prepubertal female breast should be done judiciously with small incisions and minimal tissue disruption because of the risk of damage to the underlying breast bud. The most common organisms causing breast infections are *Staphylococcus aureus*, beta-hemolytic *Streptococcus*, *E. coli*, and *Pseudomonas aeruginosa*.^{3,4} Antimicrobial coverage should initially include methicillin-resistant *Staph aureus*, until culture and sensitivity results are available.

Benign Breast Disorders

Breast pain (mastodynia or mastalgia) that is not associated with a mass or infection is usually due to hormone stimulation, possibly an imbalance in estrogen and progesterone stimulation. Symptoms may

fluctuate with the menstrual cycle. After alternate causes are sought and ruled out, the condition may be treated with oral contraceptives with reasonable results.

Although cystic disease is not typical of the adolescent age group, breast tenderness may be associated with tender "lumps" detected by the patient that fluctuate in size. Ultrasound is often normal, as the lumps are areas of normal breast tissue responding to hormone stimulation.² True cystic disease is possible, but not common, and has been linked to the use of methylxanthines. Cyst aspiration under ultrasound guidance is helpful for persistent, large, symptomatic cysts. Complex cysts should be biopsied.² Oral contraceptives may result in improved symptoms.

A fibroadenoma is the most commonly encountered breast mass in adolescents.¹ This typically presents as a rubbery, discrete, nontender mass, and may be lobular, bilateral (10%), or multiple (10–15%). There is epidemiologic evidence that the overall incidence of fibroadenomas is higher, and that fibroadenomas are often multiple and bilateral, in African-American girls, compared with white females of similar age.⁴ The average size is 2–3 cm, but a solitary fibroadenoma can be as large as 10–15 cm (giant fibroadenoma). Ultrasound characteristics include a well circumscribed, hypoechoic mass. The natural history is one of slow enlargement over time. Enlargement is more likely in pregnancy. Although some authors report spontaneous resolution of small fibroadenomas, this seems debatable. At least one longitudinal study in teens showed no resolution of discrete, solid masses followed for up to 6 years, but spontaneous resolution of the majority of fibrocystic changes.²

Histologically, Dupont describes two groups of fibroadenomas, simple and complex.⁸ Complex fibroadenoma refers to fibroadenomas with foci of cysts, sclerosing adenosis, epithelial calcifications, and papillary apocrine metaplasia. The future risk of breast cancer is higher after removal of a complex fibroadenoma for 20 years after diagnosis, but simple fibroadenomas in patients with no family history of breast cancer or proliferative disease adjacent to the fibroadenoma do not seem to be associated with an increased risk of breast cancer.⁸

The giant fibroadenoma (juvenile cellular fibroadenoma) is an uncommon variant of fibroadenoma characterized by rapid growth. The size of the lesion is generally over 5 cm.⁴ This fibroadenoma is encapsulated, benign, and the affected breast may be warm and have dilated veins over the surface. The underlying mass may cause a major distortion to the breast contour (Fig. 1). Giant fibroadenomas should be excised because they cannot readily be distinguished from cystosarcoma phylloides using physical examination, radiographic studies, or fine needle aspiration.

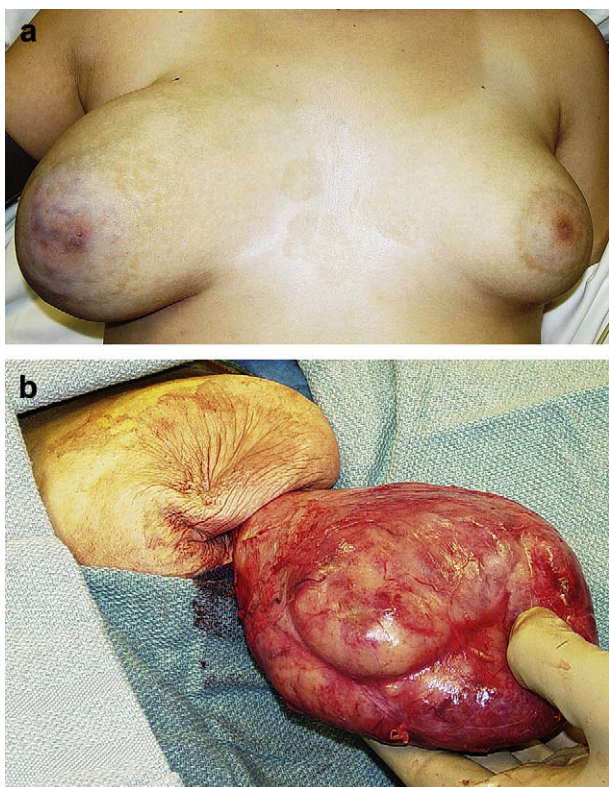


Fig. 1. (A) Adolescent with a giant fibroadenoma of the right breast causing contour distortion. Note dilated veins on the skin surface over the mass. (B) Gross appearance of the giant fibroadenoma as it is being removed from the breast.

Histology shows mitotically poor cellular stroma and minimal cytological atypia.⁴

If a young woman presents with a solitary, discrete, palpable breast mass that is clinically and radiographically consistent with a small fibroadenoma, the options are observation vs. excision. Fine needle aspiration is seldom necessary with clinical follow-up being preferable. Observation requires serial exams and ultrasounds every six months to a year to monitor size. Operation is indicated for symptomatic, large, or rapidly growing masses, if the girl or her family desire excision, or for solid masses that have ultrasound characteristics differing from a typical fibroadenoma. Mass excision can be done under local anesthesia (depending on the size), conscious sedation with local anesthesia, or general anesthesia. A circumareolar incision lends itself well to excision of most fibroadenomas and is cosmetically acceptable. Since fibroadenomas are encapsulated, the breast tissue can be divided down to the mass, and many lend themselves well to simple finger dissection as they sit in a small cavity. It is not necessary to remove a margin of normal breast tissue. If a girl decides to choose observation, consideration should be given to mass

excision by age 18, because follow-up will become more challenging unless the young lady is willing to commit to continued surveillance by an adult practitioner.

Nipple Discharge

Nipple discharge may occur at any age, including in infants, and is usually associated with benign disease.⁹ It may occur in young girls as they enter puberty and last for several months without associated underlying pathology. Brown episodic discharge may occur from Montgomery's tubercles, which are the areolar tubercles involved in lactation.

Nipple discharge may occur after exercise, or may be due to cold trauma.³ The discharge usually resolves spontaneously and manipulation will perpetuate it.

Nipple discharge that is unilateral, single duct, intermittent, and persistent should be evaluated. Appropriate imaging studies are needed if there is an associated palpable mass. A ductogram may be helpful.^{10,11} Pathologic causes of galactorrhea or milky nipple discharge include prolactin-secreting tumors, pregnancy, the post-partum state, hypothyroidism and hyperthyroidism, duct ectasia, or papillary duct hyperplasia.⁹ Hyperprolactinemia has also been associated with breast stimulation, chest trauma, and thoracotomy.¹⁰ Nipple discharge may also be associated with interrupted puberty or with primary or secondary amenorrhea. Drugs associated with nipple drainage or galactorrhea include oral contraceptives, tricyclic antidepressants, H₂ antagonists, cannabis, phenothiazines, and antihypertensive agents.^{9,10} Exfoliative cytological examination of nipple discharge and scrape smears has a low sensitivity for diagnosis.¹⁰

The disorders of papillary duct hyperplasia are rarely seen in children or adolescents.^{12,13} Intraductal papillomas arise from a proliferation of ductal cells projecting into the duct lumen. Intraductal papillomas may be solitary ductal or multiple intraductal.¹⁴ Nipple discharge may be sanguineous or serosanguinous and associated with a mass. Although an increased risk of breast cancer is associated with all forms of papilloma in adults,¹⁴ this condition has been uniformly benign in adolescents.^{12,13} A ductogram aids in diagnosis, and injection of the duct with methylene blue may aid in excision (microdochectomy).¹¹ Papillomatosis refers to papillary hyperplasia of ductal epithelium involving multiple ducts. Sclerosing papilloma/papillomatosis denotes distortion of the ductal pattern and disruption by a desmoplastic proliferation of stromal cells within and external to the ducts. Treatment of all of these disorders is by local excision. Recurrences of all types have been described.¹³

Juvenile papillomatosis is a distinct clinopathologic entity that occurs at a young age as a localized mass, is grossly nodular (“Swiss cheese appearance”), and microscopically is characterized by cysts in combination with epithelial hyperplasia and other distinct features that include marked papillomatosis, papillary apocrine metaplasia, and mild cytological atypia.^{4,15} Ultrasound features include poor mass definition, with internal echoes of variable strength, and one or more small, rounded, relatively echo-free areas mainly at the border of the lesion.¹⁶ Treatment is total resection with preservation of the normal breast. The condition is a marker for families having a relatively high frequency of breast carcinoma.^{4,15,17,18}

Mammary duct ectasia may be found in adolescent women.¹⁰ It may be associated with inflammation (periductal mastitis). Presenting symptoms include nipple discharge, noncyclical breast pain, nipple retraction, or a subareolar abscess. Ultrasound shows tubular anechoic structures or ducts filled with debris.⁵ Treatment with anti-staphylococcal antibiotics is appropriate in the presence of obvious infection or a positive culture. Mammary duct ectasia in adolescents usually resolves and does not require excision. Watchful waiting, serial breast examinations, and ultrasounds are appropriate unless the process is persistent and localized. If localized, a ductogram may prove helpful in evaluation and later excision of a focal area of involvement.¹⁰

Neoplasms and Malignant Breast Disorders

Phylloides tumors, more commonly known as cystosarcoma phylloides, are stromal tumors that are histologically classified as benign, intermediate, or malignant. However, even benign tumors may metastasize or locally recur. These are mixed epithelial and stromal neoplasms with sarcomatous changes.⁴ Benign tumors should be surgically excised with at least a 1-cm margin of normal tissue and malignant tumors may require mastectomy. Clinically palpable nodes are present in about 20% of patients and should be removed, but the primary route of metastasis is hematogenous to lung, pleura, soft tissue, bone, pancreas, and central nervous system. Re-excision is indicated for inadequate margins or local recurrence. Adjuvant therapy plays a limited role in treatment, although radiation therapy should be considered if an adequate margin cannot be achieved on the chest wall. The overall prognosis is more favorable than its presumed counterpart in adults.

Very few primary breast cancers occur in children and adolescents. The average age of the 39 cases of primary breast cancer that had been reported in children as of 2000 was 11 years (range 3–19 years),

and most were reported in girls.³ The usual presentation is with an enlarging, painless, firm, nontender, immobile, poorly circumscribed lesion located in the lateral breast quadrants. As opposed to adults, nipple discharge and retraction are uncommon. Diagnostic imaging has limited usefulness but a fine needle aspiration may be helpful.

The various histologic subtypes include secretory carcinoma and infiltrating ductal carcinoma.^{1,19,20} Secretory carcinoma is one of a small group of invasive ductal carcinomas with a favorable prognosis that infrequently spreads beyond the breast to regional lymph nodes or by hematogeneous dissemination.⁴ The tumor has a thick-walled capsule and surgical excision is the primary treatment. Adjuvant therapy is rarely needed. Medullary and inflammatory carcinomas are less common, more aggressive and often lethal. Treatment is controversial and inconsistent because of the low number of cases, but is generally guided by histologic subtype. Treatment of Hodgkin disease with chest wall radiation increases the lifetime risk for breast cancer.³

Malignant breast masses in children more commonly result from metastases than from primary lesions.¹ Examples included rhabdomyosarcoma, Hodgkin and non-Hodgkin lymphoma, melanoma, and neuroblastoma.

There are two critical genes responsible for 7–9% of all breast cancers. In girls with an inherited predisposition to breast cancer (i.e. BRCA1 on chromosome 17 and BRCA2 on chromosome 13), monthly self-examinations are recommended beginning between ages 18 and 21, and mammography at age 25–35 years. Hereditary breast cancer linked to BRCA1 gene is autosomal dominant with late onset (earliest cases in the third decade). Initial studies imply that a carrier has an 80% lifetime risk for breast cancer and a 40–60% risk for ovarian cancer.²¹ Adolescent genetic testing has been judged ethically unacceptable by most professional organizations because of the current absence of beneficial medical interventions in children that might affect the course of the disease.^{21,22}

References

1. Dehner LP, Hill DA, Deschryver K: Pathology of the breast in children. *Semin Diagn Pathol* 1999; 16:235
2. Foxcroft LM, Evans EB, Hirst C, et al: Presentation and diagnosis of adolescent breast disease. *Breast* 2001; 10: 399
3. Brandt M. In: Grosfeld JL, O'Neill JA Jr, Fonkalsrud EW, Coran AG, editors. *Pediatric Surgery*, (6th ed.), Disorders of the breast, vol. 1. Philadelphia, Mosby Elsevier, 2006, pp 885–893

4. Pettinato G, Manivel JC, Kelly DR, et al: Lesions of the breast in children exclusive of typical fibroadenoma and gynecomastia. A clinicopathologic study of 113 cases. In: Rosen PP, Fechner RE, editors. *Pathology Annual Part 2 Volume 24*. Connecticut, Appleton & Lange, 1989, pp 295–328
5. Weinstein SP, Conant EF, Orel SG, et al: Spectrum of US findings in pediatric and adolescent patients with palpable breast masses. *Radiographics* 2000; 20:1613
6. Kaplowitz PB, Overfield SE: Drug and Therapeutics and Executive Committee of the Lawson Wilkins Pediatric Endocrine Society: Reexamination of the age limit for defining when puberty is precocious in girls in the United States: implications for evaluation and treatment. *Pediatrics* 1999; 104:936
7. Garcia CJ, Espinoza A, Dinamarca V, et al: Breast US in children and adolescents. *Radiographics* 2000; 20:1605
8. Dupont WD, Page DL, Parl FF, et al: Long-term risk of breast cancer in women with fibroadenoma. *N Engl J Med* 1994; 331:10
9. Jardines L: Management of nipple discharge. *Am Surg* 1996; 62:119
10. Sakorafas GH: Nipple discharge: current diagnostic and therapeutic approaches. *Cancer Treat Rev* 2001; 27:275
11. Wong L, Chung YFA, Wong CY: Microdochectomy for single-duct nipple discharge. *Ann Acad Med Singapore* 2000; 29:198
12. Rosen PP: Papillary duct hyperplasia of the breast in children and young adults. *Cancer* 1985; 56:1611
13. Wilson M, Cranor ML, Rosen PP: Papillary duct hyperplasia of the breast in children and young women. *Modern Pathol* 1993; 6:570
14. Gutman H, Schachter J, Wasserberg N, et al: Are solitary breast papillomas entirely benign? *Arch Surg* 2003; 138:1330
15. Rosen PP, Holmes G, Lesser ML, et al: Juvenile papillomatosis and breast carcinoma. *Cancer* 1985; 55:1345
16. Kersschot EAJ, Hermans ME, Pauwels C, et al: Juvenile papillomatosis of the breast: sonographic appearance. *Radiology* 1988; 169:631
17. Bazzocchi F, Santini D, Martinelli G, et al: Juvenile papillomatosis (epitheliosis) of the breast. *Am J Clin Pathol*; 86:745
18. Taffurelli M, Santini D, Martinelli G, et al: Juvenile papillomatosis of the breast. A multidisciplinary study. *Pathol Annu* 1991; 26(Pt 1):25
19. Ferguson TB Jr, McCarty KS Jr, Filston HC: Juvenile secretory carcinoma and juvenile papillomatosis: diagnosis and treatment. *J Pediatr Surg* 1987; 22:637
20. Murphy JJ, Morzaria S, Gow KW, et al: Breast cancer in a 6-year-old child. *J Pediatr Surg* 2000; 35:765
21. Elger BS, Harding TW: Testing adolescents for a hereditary breast cancer gene (BRCA1): respecting their autonomy is in their best interest. *Arch Pediatr Adolesc Med* 2000; 154:113
22. Kopelman L: Using the Best Interests Standard to decide whether to test children for untreatable, late-onset genetic diseases. *J Med Philos* 2007; 32:375